

## Neuropathology Education

# A 32-year-old man with left temporal lobe tumor

Yoichi Nakazato<sup>1</sup> and Noriko Hosaka<sup>2</sup>

<sup>1</sup>Department of Human Pathology, Gunma University Graduate School of Medicine, Maebashi and <sup>2</sup>Division of Clinical Pathology, Nagano Municipal Hospital, Nagano, Japan

### CLINICAL HISTORY

A 32-year-old man complaining of right hemiparesia and headache underwent physical and neurological examination at Nagano Municipal Hospital. The patient has had a history of epilepsy since 10 years old, and been followed up by other hospital under a diagnosis of 'angioma'. MRI revealed an intra-axial cystic tumor, 49 × 45 mm in size, located in the left temporal lobe (Fig. 1). The lesion was low-intense on T1 and mixed hypo- and hyper-intense on T2-weighted images, with heterogeneous contrast enhancement. Intra-tumoral cyst and perifocal edema were evident. The left lateral ventricle was compressed and distorted by the tumor, and the midline structure of brain was shifted to the right side. On craniotomy a solid and hard mass, 4 × 4 × 3 cm in size, with calcification was totally excised.

### MICROSCOPIC DESCRIPTION

Paraffin sections of the specimens showed a moderately cellular tumor composed of neoplastic neuronal cells of variable size and shape (Fig. 2). Small round neuroblastic cells contained hyperchromatic nuclei and scant cytoplasm with many mitotic figures, and focally showed Indian file arrangement. There were also scattered neurocytic cells with rounded vesicular nuclei and perinuclear halo. Large ganglion cells with eccentric vesicular nuclei and ample basophilic cytoplasm were occasionally found (Fig. 3). In many areas the neoplastic tissue was separated with thin fibrovascular connective tissue into lobules. There were finely fibrillated neuropil-like matrices between cell masses. Stromal desmoplastic reaction was observed in some area. There were scattered foci of micronecrosis. Tumor cells were totally or partially positive for immunoperoxidase stains for NeuN, neurofilament protein, synap-

physin, chromogranin A, and class III beta tubulin (TUJ1), but immunostaining for GFAP was entirely negative. MIB-1-staining indices for Ki-67 antigen varied from 1.0–15.4%.

### DIAGNOSIS

Cerebral ganglioneuroblastoma.

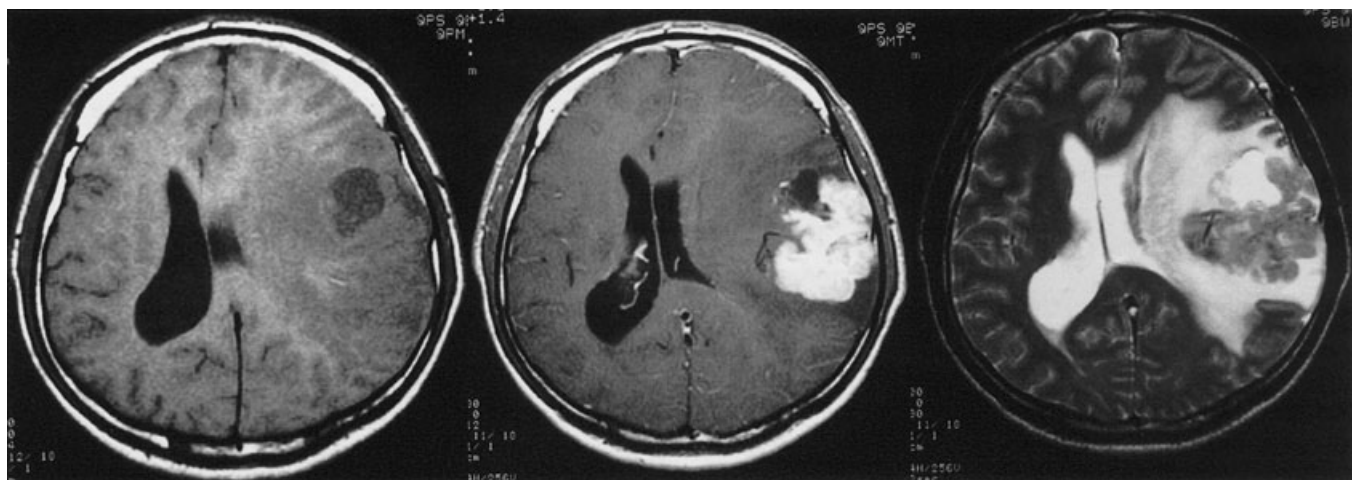
### DISCUSSION

Cerebral embryonal tumors are classified into three categories, supratentorial primitive neuroectodermal tumor (PNET), cerebral neuroblastoma and cerebral ganglioneuroblastoma, according to the World Health Organization classification.<sup>1</sup> Supratentorial PNET is composed of poorly differentiated neuroepithelial cells having the capacity for divergent neuronal and glial differentiation. Tumors with a distinct neuronal feature are classified either neuroblastoma or ganglioneuroblastoma depending on the level of neuronal differentiation. The present case consisted of neoplastic neuronal cells with a range of maturation from neuroblasts to ganglion cells, but no glial elements were identified. Immunohistochemical findings also supported a distinctive neuronal nature of this tumor. Based on these findings we made a diagnosis of cerebral ganglioneuroblastoma.

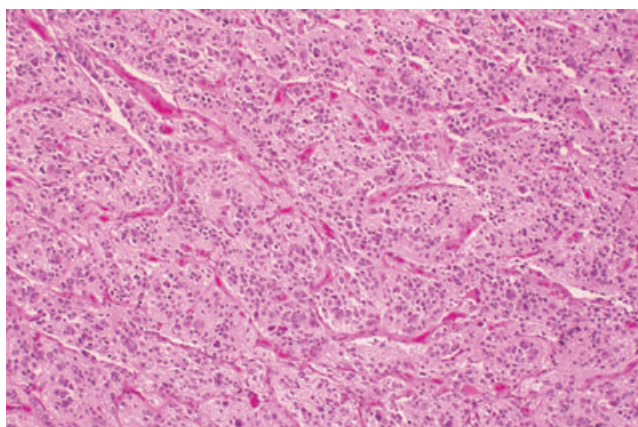
Cerebral neuroblastoma and ganglioneuroblastoma are uncommon. Most cases occur before the age of 2 years, but older children and young adults are also affected.<sup>1–3</sup> Although signs and symptoms of cerebral neuroblastic tumors are related to the site of origin, it has been shown to present with seizures, disturbances of consciousness, increased intracranial pressure or motor deficit.<sup>1</sup> It is of interest to note that the present case had developed seizures when he was 10 years of age. This early onset of the neurological symptom could indicate the origin of this tumor in his childhood era. After long dormant stage, the tumor might acquire the malignant progression with high proliferation potential. This view can be supported by the fact that the tumor showed a mixed composition of tissues

---

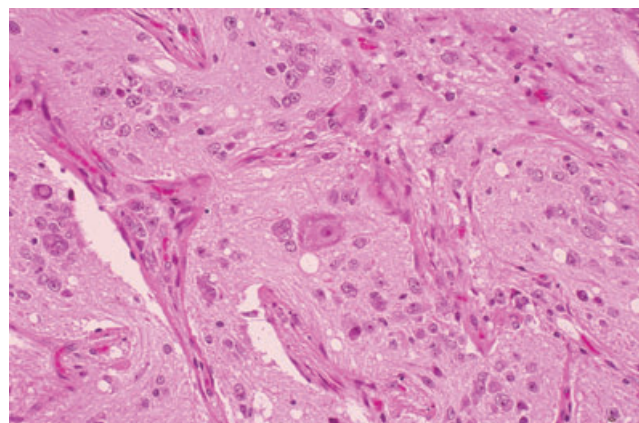
Correspondence: Yoichi Nakazato, MD, Department of Human Pathology, Gunma University Graduate School of Medicine, Maebashi, Japan. Email: nakazato@med.gunma-u.ac.jp



**Fig. 1** Neuroimaging of the tumor. Left, T1-weighted MRI shows low intensity mass lesion in the left temporal lobe; center, the tumor is heterogeneously enhanced in T1-weighted, contrast-enhanced MRI; right, T2-weighted MRI showing a mixed intensity mass with a cyst and perifocal edema in the white matter.



**Fig. 2** A moderately cellular tumor, consisting of small and medium-sized neuronal cells, is separated with fibrovascular stroma into lobules.



**Fig. 3** A ganglion cell (center) and smaller neuronal cells with finely fibrillated neuropil-like matrix. HE stain

with low and high MIB-1 indices. Further molecular cytogenetic analysis with tissue microdissection is required to prove this hypothesis.

For differential diagnosis it must exclude other embryonal tumors such as ependyoblastoma, pineoblastoma, medulloepithelioma, atypical teratoid/rhabdoid tumor and retinoblastoma. The presence of solely neuronal tumor cells and immunohistochemical expression of neuronal markers might help these differentiations. Gangliocytoma and ganglioglioma also need to be separated by the presence of immature neuroblastic elements.

## REFERENCES

1. Rorke LB, Hart MN, McLendon RE. Supratentorial primitive neuroectodermal tumour (PNET). In: Kleihues P, Cavenee WK (eds) *Pathology and Genetics of Tumours of the Nervous System*, 2nd edn. Lyon: IARC Press, 2000; 141–144.
2. Horten BC, Rubinstein LJ. Primary cerebral neuroblastoma. A clinicopathological study of 35 cases. *Brain* 1976; **99**: 735–756.
3. Bennett JP Jr, Rubinstein LJ. The biological behavior of primary cerebral neuroblastoma: a reappraisal of the clinical course in a series of 70 cases. *Ann Neurol* 1984; **16**: 21–27.