

Neuropathology Education

Reluctant hydrocephalus

Sassan Keshavarzi,¹ Homeyra Masoumi,² Pawel Jankowski,¹ Matthew Macdougall,¹ Dzenan Lulic,³
Larry Hansen² and Joseph D. Ciacci¹

¹Division of Neurosurgery, ²Department of Pathology, University of California, San Diego, California (UCSD) and
³Department of Neurosurgery, University of South Florida, Tampa, Florida (USF), USA

CLINICAL COURSE

A 32-year-old man presented to an outside emergency room for “behaving strangely”. At baseline this was a neurologically intact and fully functional person whose CT scan demonstrated enlarged lateral ventricles, prominent temporal horns and rounding of the third ventricle. None of these findings had been present on his prior scans, so he was diagnosed with hydrocephalus and was emergently transferred to University of California San Diego (UCSD) for possible failure of his ventriculoperitoneal shunt (VPS). On presentation to UCSD he was minimally verbal and the family had no idea why he had previously been shunted. His shunt was tapped and CSF chemistry was significant for glucose of 73 mg/dL and total protein < 10 mg/dL. With no indication of bacterial meningitis, the presumption was that his shunt was obstructed. The following day the patient was taken to the operating room for a VPS revision. Postoperatively his examination results dramatically improved and he was more conversant. On postoperative day #3 (POD) his mental status declined and he was taken for another revision of his VPS. Once again the proximal catheter was exchanged. The patient had improvement in his neurological status, but after a few days he started to decline and on POD#6 he was taken to the operating room for his third VPS revision. Three months after this third revision he represented to UCSD for a decline in mental status. He was taken to the operating room for another VPS revision and his CSF chemistry was impressive for glucose of 68 mg/dL and total protein of 425 mg/dL. His proximal catheter was obstructed and exchanged. One month after his fourth revision he represented to UCSD with altered mental status. His head CT scan demonstrated grossly enlarged lateral and third ventricles with a rather modest fourth ventricle (Fig. 1). He

was taken to the operating room for a VPS revision for shunt failure and third ventricular fenestration for possible obstructive hydrocephalus. During the third ventricular fenestration the senior surgeon (JDC) appreciated a cystic mass that was resected and sent for pathology. Subsequently, over the next 6 month the patient did not represent for decline in neurological status and has been stable in all subsequent post-operative visits to our clinic.

PATHOLOGIC FINDINGS

We identified a cysticercosis cyst which was round to oval in shape. Histologically, the cyst wall had three layers: (i) an outer eosinophilic cuticular layer beneath which are bundles of muscle fibers; (ii) a middle or cellular layer with small, evenly distributed dark-staining nuclei; and (iii) an inner or reticular layer. It was particularly pleasing to be able to appreciate and identify the intact sucker (Fig. 2).

DIAGNOSIS

Cysticercosis cellulose cyst of the third ventricle.

DISCUSSION

Cysticercosis is the most common parasitic disease in the world and has infected over 50 million people.^{1–3} The infection is endemic to Mexico, Central and South America, Asia and India.^{4,5} The neurologic manifestation is neurocysticercosis, which is the most prevalent brain infection world-wide.^{6–8} This is the leading cause of adult-onset seizures in the world.^{9–12} In the US there are over 1000 new cases of neurocysticercosis diagnosed each year.^{2,13} Not surprisingly in southwestern US (i.e., San Diego, California) where a large population of the emigrants originate from endemic areas such as Mexico, cysticercosis is an increasingly common problem. Studies point to neurocysticercosis

Correspondence: Sassan Keshavarzi, MD, Division of Neurosurgery, University of California, San Diego, 200 W. Arbor Drive, Suite 8893, San Diego, CA 92103-8893, USA. Email: skeshavarzi@ucsd.edu

Published online 25 January 2010.

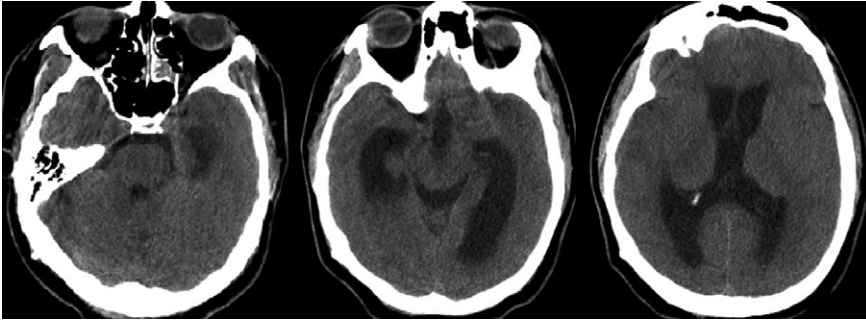


Fig. 1 CT scan of the head demonstrating dilation of the ventricular system: bilateral lateral ventricles and third ventricle. Of significance is the out-of-proportion small fourth ventricle indicating an obstruction within the ventricular system between the third and fourth ventricles.

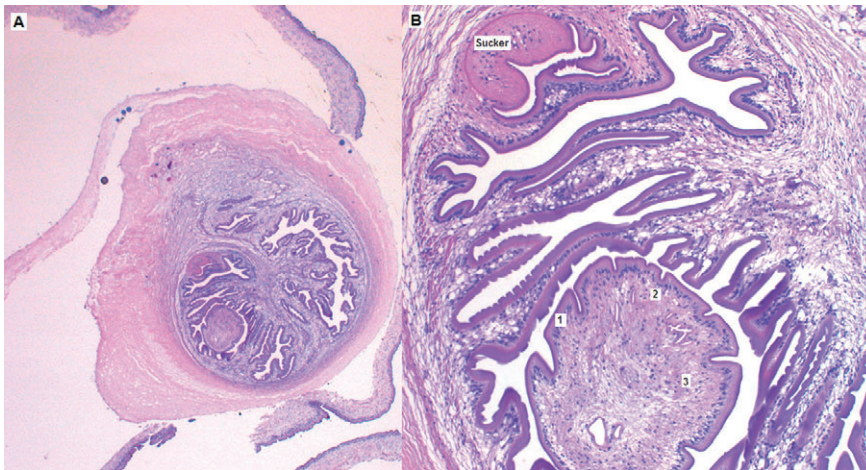


Fig. 2 (A) Cysticercosis cellulose cyst with its sucker and surrounding reactive fibrocollagenous tissue of the brain. (B) The cyst is composed of a three-layered wall: (i) outer eosinophilic cuticular layer; (ii) a middle layer with small, dark-staining nuclei; and (iii) an inner layer containing loosely arranged fibrils ($\times 200$).

being the cause of close to 10% of cases that present to emergency rooms in Los Angeles, California, with new-onset seizures.^{12,14}

Taenia solium has a life-cycle that starts at the larval stage in pigs and human infection takes place with ingestion of the cyst from uncooked pork. However, this infection is not limited to those who eat pork as fecal-oral contamination takes place via infected food handlers. Thus, even vegetarians can develop cysticercosis and so suspicion should be high in endemic areas.^{2,7} If neurocysticercosis is suspected, brain CT scan with and without contrast is typically the first step in diagnosis, typically demonstrating a contrast-enhancing lesion. If the scolex is present, that is pathognomonic for neurocysticercosis.

Even with pathognomonic results on imaging often the patient has to have a biopsy and histopathologic examination. The cysts of cysticercosis are round to oval with a thin translucent membranous wall filled with a clear fluid. This cyst wall has three layers: an outer eosinophilic cuticular layer beneath which are bundles of muscle fibers; a middle or cellular layer with small, evenly distributed dark-staining nuclei; and an inner or reticular layer containing loosely arranged fibrils, excretory canaliculi, and calcareous corpuscles. Suckers and a rostellum with hooklets may be observed. One may also appreciate a prominent acute

and chronic inflammatory response of the surrounding brain parenchyma to the degenerating organism. With a definitive diagnosis the common treatment of neurocysticercosis is albendazole and steroids. The treatment for intraventricular cysts is twice the dose of albendazole.

REFERENCE

- Castillo M. Imaging of neurocysticercosis. *Semin Roentgenol* 2004; **39**: 465–473.
- Hawk MW, Shahlaie K, Kim KD, Theis JH. Neurocysticercosis: a review. *Surg Neurol* 2005; **63**: 123–132.
- Psarros TG, Zouros A, Coimbra C. Neurocysticercosis: a neurosurgical perspective. *South Med J* 2003; **96**: 1019–1022.
- Garcia HH, Del Brutto OH. *Taenia solium* cysticercosis. *Infect Dis Clin North Am* 2000; **14**: 97–119.
- Sawhney IM, Singh G, Lekhra OP, Mathuriya SN, Parihar PS, Prabhakar S. Uncommon presentations of neurocysticercosis. *J Neurol Sci* 1998; **154**: 94–100.
- Proaño JV, Madrazo I, García L, García-Torres E, Correa D. Albendazole and praziquantel treatment in neurocysticercosis of the fourth ventricle. *J Neurosurg* 1997; **87**: 29–33.

7. Garcia HH, Gonzalez AE, Evans CA, Gilman RH, for the Cysticercosis Working Group in Peru. *Taenia solium* cysticercosis. *Lancet* 2003; **362**: 547–556.
8. Shandera WX, White AC Jr, Chen JC, Diaz P, Armstrong R. Neurocysticercosis in Houston, Texas. A report of 112 cases. *Medicine (Baltimore)* 1994; **73**: 37–52.
9. Del Brutto OH, Roos KL, Coffey CS, Garcia HH. Meta-analysis: cysticidal drugs for neurocysticercosis: albendazole and praziquantel. *Ann Intern Med* 2006; **145**: 43–51.
10. Del Brutto OH, Santibañez R, Noboa CA, Aguirre R, Diaz E, Alarcón TA. Epilepsy due to neurocysticercosis: analysis of 203 patients. *Neurology* 1992; **42**: 389–392.
11. Garcia HH, Evans CA, Nash TE *et al.* Current consensus guidelines for treatment of neurocysticercosis. *Clin Microbiol Rev* 2002; **15**: 747–756.
12. García HH, Pretell EJ, Gilman RH *et al.* A trial of antiparasitic treatment to reduce the rate of seizures due to cerebral cysticercosis. *N Engl J Med* 2004; **350**: 249–258.
13. Singhi P, Singhi S. Neurocysticercosis in children. *J Child Neurol* 2004; **19**: 482–492.
14. Ong S, Talan DA, Moran GJ *et al.* Neurocysticercosis in radiographically imaged seizure patients in U.S. emergency departments. *Emerg Infect Dis* 2002; **8**: 608–613.