

Neuropathology Education

An 11-month-old girl with arrested psychomotor development and lactic acidosis

Masashi Mizuguchi,¹ Masayuki Itoh² and Hiroshi Ozawa³

¹Department of Pediatrics, Jichi Medical School, Minamikawachi, ²Department of Mental Retardation and Birth Defect Research, National Institute of Neuroscience, NCNP, Kodaira and ³Department of Pediatrics, Tokyo Metropolitan Hachioji Children's Hospital, Hachioji, Japan

CLINICAL HISTORY

This female patient was the second-born child to non-consanguineous, healthy parents. The first child, her elder brother, had respiratory distress and metabolic acidosis at 3 days of age, and died at 5 days. After an uneventful gestation for 39 weeks, this patient was born by normal delivery. Immediately after birth, she weighed 2608 g and looked well. Twenty-one hours later, however, she became dyspneic and underwent mechanical ventilation until 8 days of age. Blood examination revealed severe lactic acidosis (pH 6.97, PaCO₂ 23 mmHg, base excess -26 mEq/l, lactate 135 mg/dL), which was treated with sodium bicarbonate and thiamine. Despite improvement of her general condition, metabolic acidosis persisted. At the age of 1 month, lactate and pyruvate levels were 36.8 and 1.80 mg/dL in the blood (normal values, 7.0–25.0 and 0.6–1.35 mg/dL), and 51.1 and 2.77 mg/dL in the cerebrospinal fluid (normal values, 11.1–16.3 and 0.75–1.29 mg/dL), respectively. An analysis of mitochondrial DNA (mtDNA) of the peripheral blood cells disclosed a T-to-G mutation at nucleotide position 8993. When she was discharged at 2 months of age, she was unresponsive to environmental stimuli, and had spastic paraplegia. She began to follow objects with her eyes at 2 months, to show social smile at 3 months, to control her head at 5 months, to roll over at 7 months, and to sit unsupported at 7 months. Cranial MRI at 4 months of age showed no abnormal signals in the brain.

After 8 months of age, she showed no further development. She smiled less frequently than previously. Dysph-

agia and stridor became more prominent. Ubidecarenone and levocarnitine were prescribed. MRI at 10 months of age showed T₁ and T₂ prolongation of the bilateral putamina, caudate nuclei, periaqueductal gray matter, and substantia nigra (Fig. 1). Spastic tetraparesis worsened. At 10.5 months, sudden appearance of nystagmus was followed by difficulty in sucking milk, loss of smile and other responses, and irregular respiration. When she was admitted again, she showed deep coma, no spontaneous movements, and minimal response to painful stimuli. The pupils were meiotic and unresponsive to light. There were marked muscle hypotonia and positive pathological reflexes. Blood examination showed lactic acidosis (pH 7.44, PaCO₂ 21 mmHg, base excess -8 mEq/l, lactate 72.3 mg/dL, pyruvate 2.05 mg/dL). Despite mechanical ventilation, and administration of sodium dichloroacetate and cytochrome C, her condition deteriorated further with intercurrent pneumonia, appearance of mydriasis, and loss of spontaneous respiration. Cranial computed tomography showed hypodensity of the entire brain. Electroencephalogram and auditory evoked response showed a total loss of electrical activity. Two weeks later, she died at the age of 11 months.

NEUROPATHOLOGICAL FINDINGS

The brain was swollen, soft, and congested, weighing 920 g (mean brainweight of 11-month-old infants: 852 g). There was bilateral uncal herniation, and subarachnoid hemorrhage around the Sylvian fissures and ventral brainstem. On sectioning of the brain, the bilateral striatum was whitish and sclerotic. The thalami, hypothalami, and periaqueductal gray matter of the midbrain were black in color. The tegmentum of the pons and medulla oblongata showed gray-brown discoloration.

Histologically, there were symmetrical foci of coagulative necrosis in the bilateral putamina and thalami, the bor-

Correspondence: Masashi Mizuguchi, MD, Department of Pediatrics, Jichi Medical School, 3311-1 Yakushiji, Minamikawachi, Kawachi-gun, Tochigi 329-0498, Japan. Email: mmizuguc@jichi.ac.jp

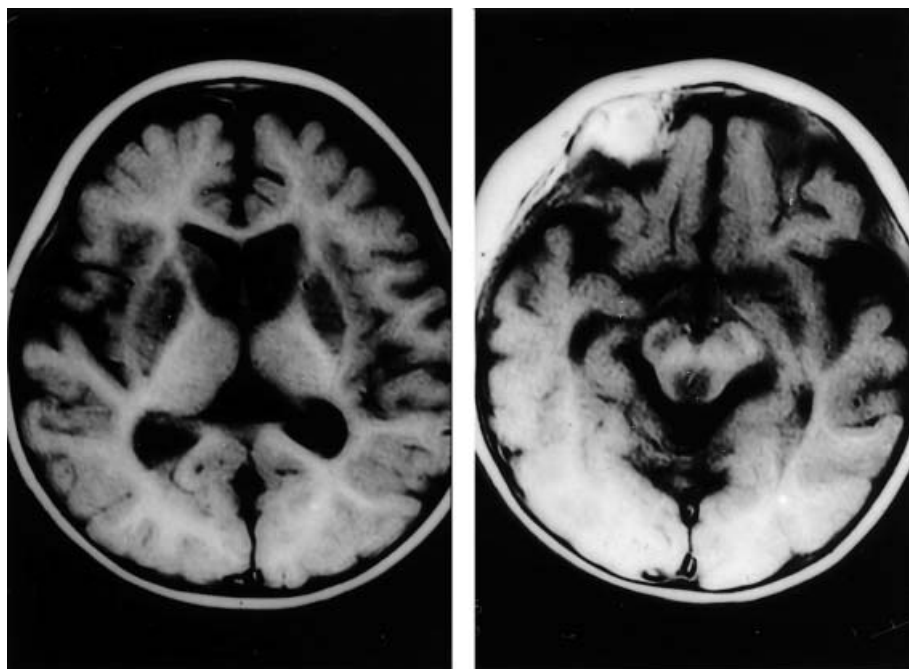


Fig. 1 Cranial T₁-weighted magnetic resonance images at 10 months of age. Symmetrical lesions are present in the bilateral putamina, caudate nuclei, periaqueductal gray matter, and substantia nigra.

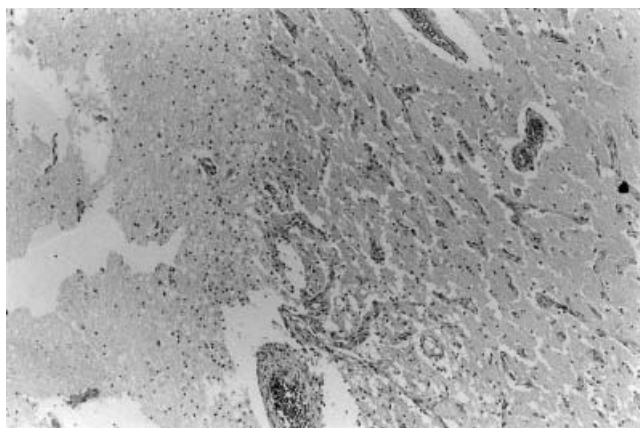


Fig. 2 Putaminal lesion showing coagulative necrosis (left), infiltration of macrophages (middle), and vascular proliferation (right) (HE staining, $\times 50$).

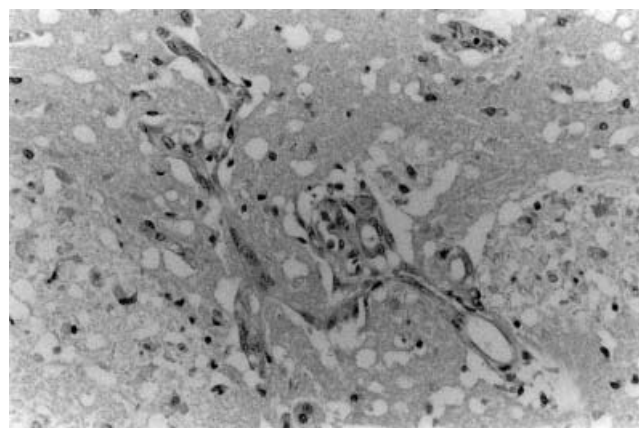


Fig. 3 Putaminal lesion showing a spongy change of the neuropil, severe loss of neurons, moderate astroglia, vascular proliferation, and endothelial hypertrophy (HE staining, $\times 190$).

der of which was infiltrated by macrophages (Fig. 2). The rest of the basal ganglia and diencephalon showed rarefaction of the neuropil and poor staining of myelin, as well as moderate to severe neuronal loss and astroglia (Fig. 3). The blood vessels, in particular the capillaries, were markedly increased in density, and often showed endothelial hypertrophy. Small foci of necrosis were also noted in the substantia nigra, periaqueductal gray matter, and pontine tegmentum. The surrounding tissue showed a spongy change and vascular proliferation. Neuronal loss and astroglia were less prominent in the tegmental lesions than in the basal ganglia and substantia nigra (Fig. 4).

The cerebral cortex was unremarkable except for ischemic neuronal changes. The cerebellum showed a mod-

erate loss of Purkinje and granular cells in the cortex, and multiple linear infarcts in the white matter.

DIAGNOSIS

Leigh syndrome caused by mtDNA mutation (T-to-G) at 8993.

DISCUSSION

The clinico-pathological phenotype of the present case was typical of Leigh syndrome. The clinical aspects of this syndrome are characterized by autosomal recessive

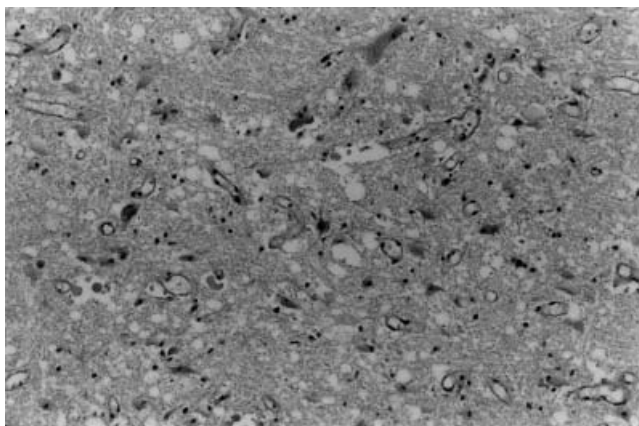


Fig. 4 Lesion of the medullary reticular formation showing a spongy change of the neuropil, mild loss of neurons, mild astrogliosis, and vascular proliferation (HE staining, $\times 120$).

or maternal inheritance, onset under 2 years of age (in more than 90% of cases), and variable signs such as growth and developmental retardation, hypotonia, irregular respiration, bulbar palsy, pyramidal signs, nystagmus, abnormal ocular movements, ataxia, and seizures. Biochemical examinations of the blood and cerebrospinal fluid detect an elevated level of lactate and pyruvate. Muscle biopsy often demonstrates the deficiency of cytochrome C oxidase. Cranial computed tomography and MRI reveal bilateral symmetrical lesions in the basal ganglia and brainstem.

The pathologic substrate of these imaging findings is multifocal, gray-brown lesions that predominantly affect the deep gray matter and show either softening or cavitation. The neuropil in these lesions shows rarefaction and spongy changes, which finally progress into necrosis. There is loss of both myelin and axons. Proliferation of blood vessels is prominent and associated with endothelial hypertrophy. Although well preserved compared to the background tissue, neuronal cell bodies also progressively decrease in number. There are infiltration of macrophages and reactive astrogliosis, the degree of which varies according to the severity and oldness of the lesions. In the present case, the lesions of the striatum and substantia nigra, which had been demonstrated by MRI a month prior to the infant's death, showed pathologic changes more severe and older than those of the brainstem tegmentum.

Variable mutations have been identified as the cause of Leigh syndrome.¹ The most common (20–25%) of these mutations cause deficiency of complex V (adenosine triphosphatase) of the mitochondrial respiratory chain, and include mutations such as T-to-G/C at 8993 and T-to-C/G at 9176 of mtDNA. About 10% of cases have a deficiency of complex IV (cytochrome C oxidase) caused by

mutation of genes in nuclear DNA, such as *SURF-1* on chromosome 9 and *LRPPRC* on chromosome 2. Less than 5% of cases have deficiency of the pyruvate dehydrogenase complex, often resulting from mutation of the *E1 α* gene on the X chromosome. A smaller number of patients have abnormal transfer RNA produced by mtDNA mutations such as A-to-G at 3243 and A-to-G at 8344, or deficient complex I (NADH-ubiquinone oxoreductase) resulting from mutations of nuclear genes, such as *NDUFS7* and *NDUFV1*.¹ Deletions of mtDNA can also produce brain lesions similar to those of Leigh syndrome.^{2,3} However, the causative mutation cannot be identified in about 60% of the cases.

In general, correlation between genotypes and phenotypes tend to be complicated in mitochondrial disorders, and the situation in Leigh syndrome is a typical example. The marked genetic heterogeneity of this syndrome is indicated by the large number of causative mutations described above. Furthermore, some of these mutations are usually manifested with phenotypes distinct from Leigh syndrome. For example, the A-to-G mutation at 8344 is typically associated with myoclonic epilepsy associated with ragged-red fibers (MERRF), and the A-to-G mutation at 3243 with mitochondrial myopathy, encephalopathy, lactic acidosis, and stroke-like episodes (MELAS). The same mutations give rise to these disorders when the ratio of mutant mtDNA is moderate to high, whereas they tend to cause Leigh syndrome when the ratio is very high. Even in the former disorders, Leigh-like lesions often appear at advanced stages of the disease.

Taken together, these facts indicate that Leigh syndrome is a condition too ill-defined to remain as a clinicopathological entity. The authors prefer the term 'Leigh-type neuropathology',² which denotes a typical pattern of pathology and imaging findings when the brain is affected by various mitochondrial disorders. From a practical viewpoint, however, there is still a reason to use the term 'Leigh syndrome' for the time being because the etiology remains unclear in many patients, thereby excluding a more refined diagnosis.

ACKNOWLEDGMENTS

We thank Professor Yuichi Goto (Department of Mental Retardation and Birth Defect Research, National Institute of Neuroscience, NCNP) for the DNA diagnosis of this patient.

REFERENCES

1. DiMauro S, Andreu AL, deVivo DC. Mitochondrial disorders. *J Child Neurol* 2002; **17**: S35–S47.

2. Santorelli FM, Barmada MA, Pons R, Zhang LL, DiMauro S. Leigh-type neuropathology in Pearson syndrome associated with impaired ATP production and a novel mtDNA deletion. *Neurology* 1996; **47**: 1320–1323.
3. Saitoh S, Momoi MY, Ohki T, Yamagata T, Tsuru T, Mizuguchi M. A large-scale mitochondrial DNA deletion causing progressive ataxia. *J Child Neurol* 1998; **13**: 573–575.